

# Class V amalgam cavity preparation

د. زنبق عزیز

Lec 7:

## Definition

**Class V Caries:** Smooth surface carious lesions located on the gingival/cervical third of labial/buccal and more rarely the lingual surfaces of all teeth.

Simple lesion as it mostly involves one surface of a tooth as shown in fig1.

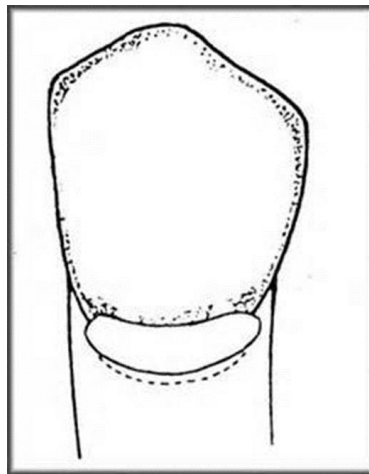


Fig1: CL V

**Caries is not only the reason of cavitation, abrasion and erosion may also responsible**

- **Erosion:** tooth loss at the cervical area due to nonbacterial acid attack.

- **Abrasion:** tooth loss at the cervical area of the tooth due to abrasive slurry between two surfaces (mechanical action) e.g: tooth brush – dentifrice abrasion.

In both cases there is no caries if we prepare a class V cavity it is better to be filled by amalgam, because of high abrasive resistance of amalgam.

### **Restorative materials for Class V cavity**

- ✓ Amalgam
- ✓ Composite
- ✓ Resin modified GIC
- ✓ Compomers

### **Indications for amalgam as restorative material**

- ✓ Non-esthetic areas
- ✓ Areas where access and visibility are limited
- ✓ Areas where moisture control is difficult
- ✓ Areas those are significantly deep gingivally.

### **Contraindications for amalgam as restorative material**

- ✓ Esthetically important areas

### **Advantages of amalgam as restorative material**

- ✓ Amalgam restorations are stronger than other direct restorations
- ✓ Easier to place
- ✓ less expensive to the patient
- ✓ Usually easier to finish and polish

## **Disadvantages of amalgam as restorative material**

- ✓ The primary disadvantage amalgam restorations are that they are metallic and non-esthetic.
- ✓ The preparation for an amalgam restoration typically requires 90-degree cavo-surface margins specific and uniform axial depths, and incorporation of secondary retentive features, all of which results in a less conservative preparation than that for other esthetic restorative materials.

## **Clinical technique for class V amalgam preparation**

### **Initial Clinical Procedures**

- Local Anaesthesia
- Isolation (rubber dam recommended)

### **Tooth preparation**

#### **I. OUTLINE FORM**

- Rounded trapezoid in gingival 1/3.
- Conforms to the tooth shape, typical caries location, and site of plaque accumulation.
- Primarily determined by the location and size of the caries/defect or old restorative material
- Cavo-surface margins should be extended to sound tooth structure while maintaining a limited axial depth of 0.5 mm inside the DEJ and 0.75 mm inside the cementum (when on the root surface)

- Using round bur to start entry to the cavity, the direction of the bur should be perpendicular to the buccal (or palatal) surface of the tooth , then using a tapered fissure bur of suitable size, enter the carious lesion to a limited initial axial depth of 0.5 mm inside the DEJ.
- This depth is usually 1 to 1.25 mm total axial depth, depending on the incisogingival/occlusogingival location (The enamel is considerably thicker occlusally and incisally than cervically)
- However, if the preparation is on the root surface, the axial depth is approximately 0.75 mm.
- Extend the preparation incisally, gingivally, mesially, and distally until the cavosurface margins are positioned in sound tooth structure providing the desired outline form
- Preparation of the axial wall depth 0.5 mm inside the DEJ results in a uniform depth for the entire preparation.
- Because the axial wall follows the mesiodistal and incisogingival/occlusogingival contours of the facial surface of the tooth, it will usually be convex in both directions as shown fig 2.
- The mesial, distal, gingival, and incisal walls of the tooth preparation are perpendicular to the external tooth surface to keep the cavosurface angle 90 degree and to follow the direction of enamel rods, they usually diverge facially.
- Consequently, this form provides no inherent retention, and retention form must be provided.

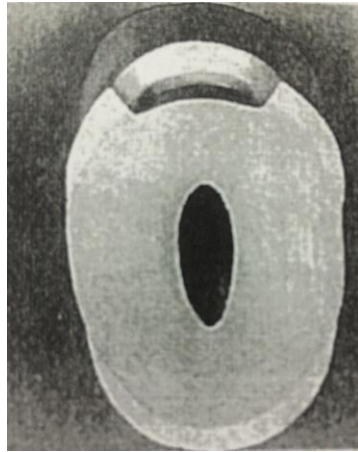


Fig 2: convex axial wall

## II. Resistance form

□ Depth of the cavity is 1.5 mm: the axial wall of the cavity should not be flat, if we do so will not have even depth of the cavity because of convexity of tooth structure, so the axial wall should be slightly convex.

cavosurface line angle (90-110).

- Rounded internal line angles
- Removal of unsupported enamel
- Occlusal and gingival walls should be perpendicular to the long axis of the tooth and parallel to each other, any convergence of these walls will create unsupported enamel.

## III. Retention form:

Use a No. 1/4 bur to prepare two retention grooves, one along the incisioaxial line angle and the other along the gingivoaxial line angle (figure 3) 0.2-0.3mm inside the DEJ

The handpiece is positioned so that the No. 1/4 bur is directed generally to bisect the angle formed at the junction of the axial wall and the incisal/occlusal or gingival wall

- Ideally the direction of the incisal (i.e., occlusal) groove is slightly more incisal (i.e., occlusal) than axial, and the direction of the gingival groove is slightly more gingival than axial.
- Mesial and distal walls should be slightly diverge.

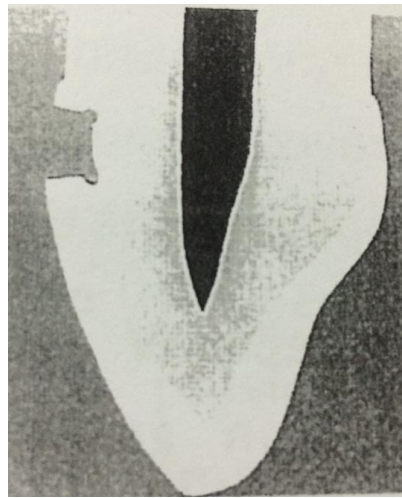


Fig 3: retentive grooves of CLV

### III. Final preparation:

- Removal of any remaining infected dentin
- Pulp protection
- Finishing external walls
- Cleaning & inspecting

### Summary

- **Outline form** – Rounded Trapezoid
- **Axial Depth**- 1- 1.25 mm ( when margins in enamel), 0.75 mm when margins are in cementum ( Root surface)
- **Axial wall**- 0.5 mm inside DEJ, Convex in all directions to conform the external tooth contour

- **Divergent Incisal, Gingival, Mesial & Distal walls-** follow the direction of enamel rods
- **Retention features-** Grooves & Coves- 0.2- 0.3 mm inside DEJ using  $\frac{1}{4}$  round bur